

ABCs of ECGs

Amanda M. Shelby, RVTg, VTS (Anesthesia & Analgesia)

Gasgirl.vts@gmail.com

Monitoring ECGs is important in critical patients and during the peri-anesthetic period. AAHA and the ACVAA anesthetic monitoring guidelines include monitoring of circulation. ECG monitoring provides unique assessment of cardiovascular rate and rhythm. Routine ECG assessment allows for early detection of potentially life threatening arrhythmias and thus early treatment. Within this presentation, we will learn a systematic approach to ECG interpretation and identify common arrhythmias. We will also explore causes and effective treatments. Upon completion, participants will be able to interpret common arrhythmias from ECGs, understand their causes and treatment options.

*These notes are set up to serve as an interactive worksheet.

Applying ECGs (USA standard) to a patient:

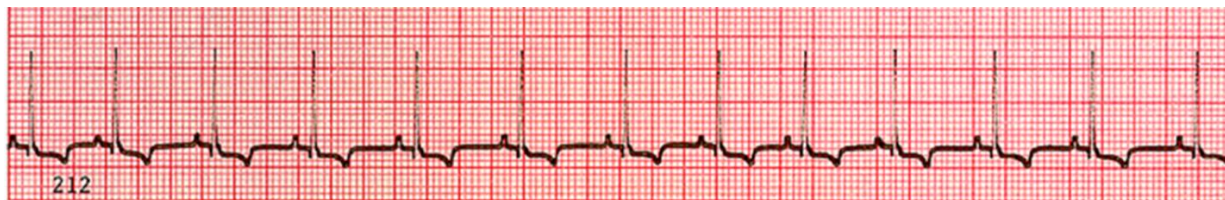1. Black electrode = left arm (front limb)
2. White electrode = right arm (front limb)
3. Red electrode = left leg (hind limb)

Step by step ECG interpretation:

1. Identify heart rate. Fast or slow.
 - a. At 25 mm/s speed, 1 big pen = 6 sec X 10 = estimate beats
 - b. At 50 mm/s speed, 1 big pen = 3 sec X 20 = estimated beats
2. P for every QRS; QRS for every P
3. Regular or Irregular (is the waveform predictable)

Answering these questions often direct you to 1 or 2 possible arrhythmias...

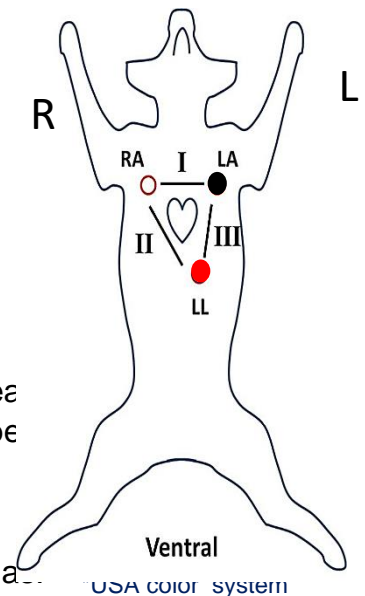
Examples:

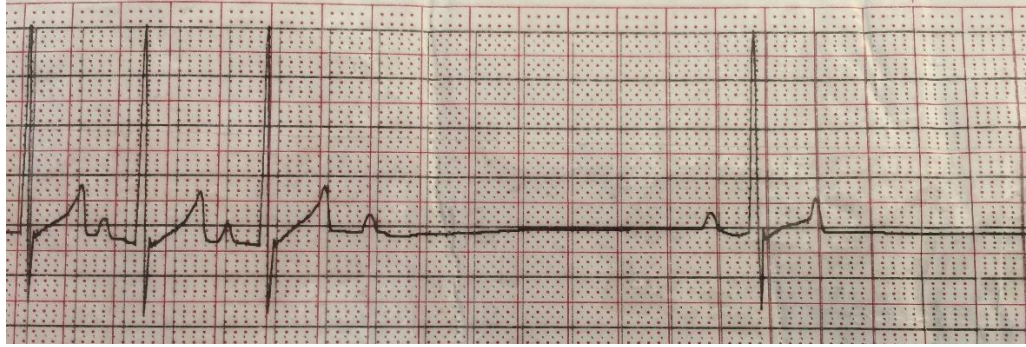


Identification:

Causes:

Treatment:

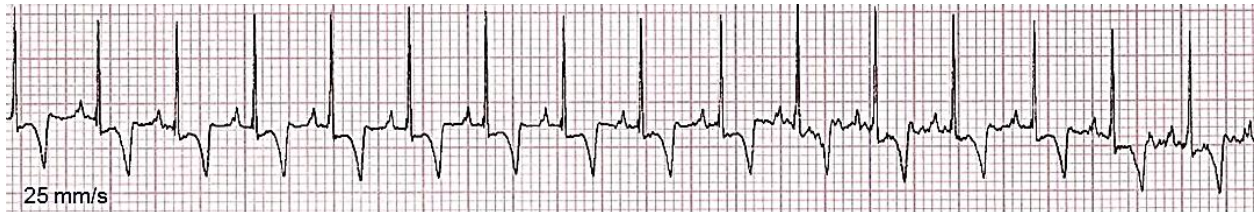




Identification:

Causes:

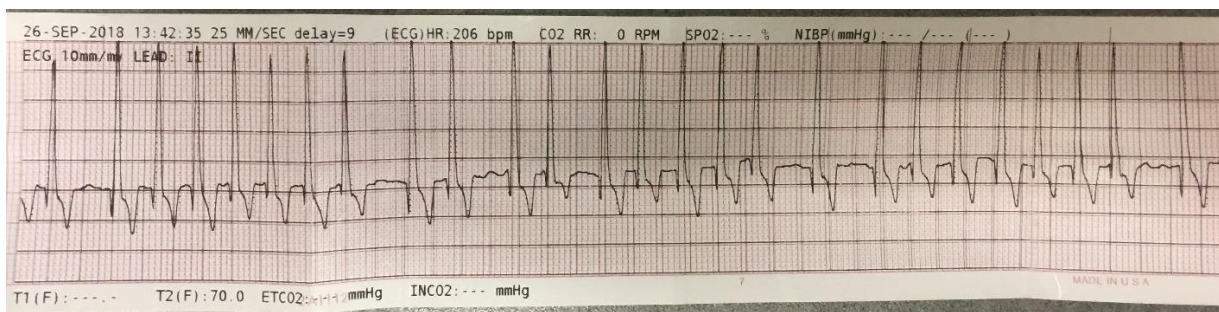
Treatment:



Identification:

Causes:

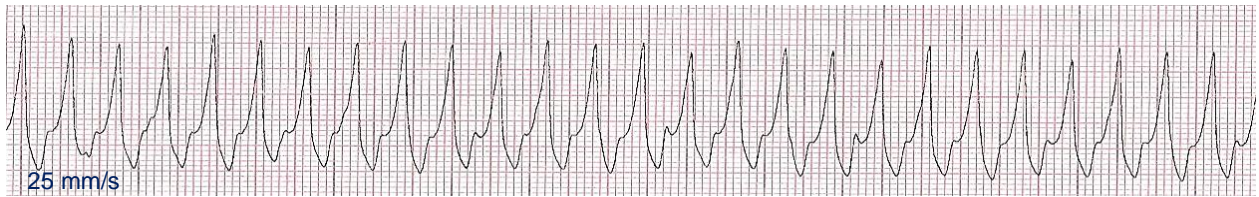
Treatment:



Identification:

Causes:

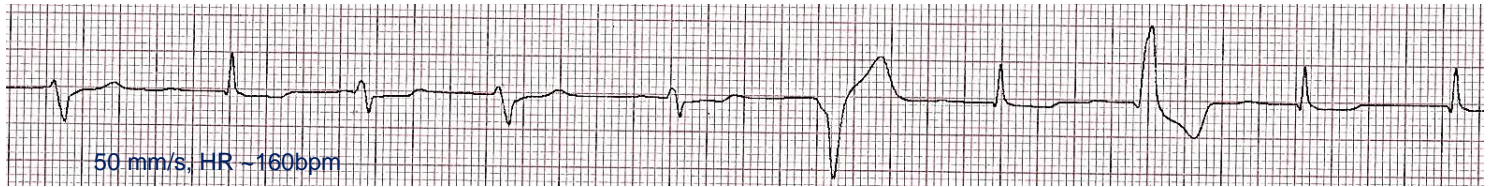
Treatment:



Identification:

Causes:

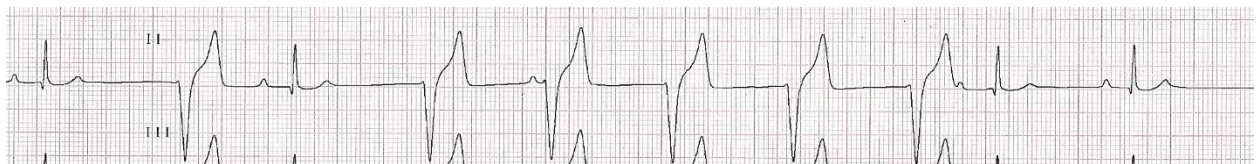Treatment:



Identification:

Causes:

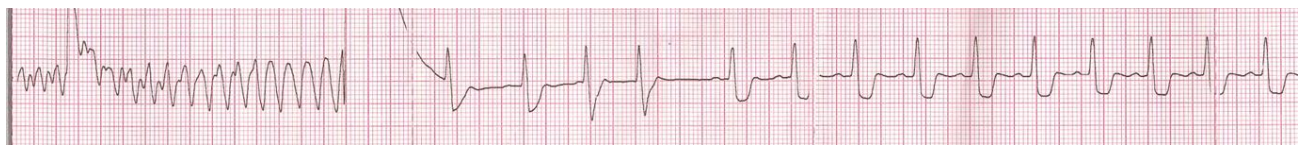Treatment:



Identification:

Causes:

Treatment:



Identification:

Causes:

Treatment: